



**PATIENT**

Lorenzo Wallace

**SPECIES**

Canine

**BREED**

Greyhound

**SEX**

Male Neutered

**AGE**

3 years

**WEIGHT**

77lbs

**INTERPRETED BY**

Maggie Machen  
Lamy, DVM  
DACVIM (Cardiology)

**IMAGING PERFORMED BY**

Pamela Harrigan,  
RDCS

**HOSPITAL NAME**

Mass Veterinary Services

**REFERRING VET**

Dr. Masloski

**INVOICE**

24351

**DATE**

5/24/22

**PRESENTING CLINICAL SIGNS**

History: Lorenzo was noted to have a radiographic cardiomegaly in February. He is eating well with some "hacking" noted during occasionally after eating. No exercise intolerance or dyspnea but does tire easily after a sprint. Needs dental prophylaxis. On exam: NSR, grade IV/VI murmur with PMI left apical area radiating to right, PSS, lung fields clear. BP: 180mmHg x 5 \*No sedation for study.

**ECHOCARDIOGRAM FINDINGS**

2D, m-mode, color flow and Doppler imaging is available.

**Left ventricle:** The LV chamber is normal with mild to moderate LV hypertrophy. The endocardium appears hyperechoic. Mild papillary muscle hypertrophy.

**Left atrium:** The left atrium is mild to moderately enlarged.

**Mitral valve:** The mitral valve is mildly thickened. Mild eccentric mitral regurgitation.

**Aortic valve/aorta:** Significant subaortic narrowing with severely increased flow through the region. Max PG 81mmHg. The aortic valve appears trileaflet and mildly thickened. Mild aortic insufficiency. Prominent coronary arteries.

**Right ventricle:** Normal right ventricular diameter and morphology indicating no overt evidence of pulmonary arterial hypertension.

**Right atrium:** Normal RA dimension.

**Tricuspid valve:** The tricuspid valve appears thickened with mild TR; borderline velocity.

**Pulmonic valve/pulmonary artery:** The pulmonic valve is normal in morphology and mobility. No pulmonic insufficiency. Normal RVOT velocity; laminar flow.

**Pericardium/other:** No pericardial or pleural effusion noted. No congenital shunts appreciated. No obvious cardiac masses.

**Heart rhythm:** ECG reveals a sinus rhythm with an average HR of 10bpm.

**2-Dimensional Measurements**

Ao diam (cm)	2.6
LA diam (cm)	4.1
LA:Ao (Swe)	1.6
IVS thickness (cm)	1.6
LVID diastole (cm)	4.5
PW thickness (cm)	1.8
LVID systole (cm)	2.7
FS (%)	40

**Doppler Measurements**

PV Vmax (m/s)	1.3
AoV Vmax (m/s)	4.5
MR Vmax (m/s)	NM
TR Vmax (m/s)	2.8
TR PG (mmHg)	32

**INTERPRETATION OF THE FINDINGS**

The cause of the murmur is severe subaortic stenosis (SAS) causing elevated blood flow velocity through the LVOT. The valve is also mildly thickened; however, the primary issue appears subvalvular. A mild aortic leak is noted, which should be monitored going forward.

The LV walls are mild to moderately increased indicating pressure overload of the left heart. The outflow velocity places the disease in the severe/marked category which is highly concerning. The mitral and tricuspid valves both appear mildly abnormal as well with mild MR and TR; however, this is comparatively insignificant in light of LVOT changes. No additional issues are identified.

No surgical intervention is widely available at this time; however, advanced options could be discussed at an academic institution. Medical management through heart rate control is recommended as below, in hopes of decreasing the obstruction long term.



**PATIENT**  
Lorenzo Wallace

Prognosis is guarded yet highly variable, with many dogs in the severe category succumbing to malignant arrhythmias by mid-life and others maintaining asymptomatic status long term. Serial echocardiography is recommended lifelong to assess for progression and risk for complication.

**SPECIES**  
Canine

**BREED**  
Greyhound

**SEX**  
Male Neutered

**AGE**  
3 years

**WEIGHT**  
77lbs

**INTERPRETED BY**  
Maggie Machen  
Lamy, DVM  
DACVIM (Cardiology)

**RECOMMENDATIONS**

- Institute atenolol to effect: 0.5-1.5mg/kg SID-BID (up-titrate to desired effect). Goal is to suppress heart rate <130bpm even with stress/activity. \*NOTE: This patient's resting HR is reportedly low on exam. If this is persistently true, this medication may not be necessary. Follow up HR assessment is advised prior to institution.
- Consider referral as discussed to explore surgical options if desired.
- Consider hydrocodone for the cough if indicated.
- Omega fatty acid supplementation and mild salt restriction may be of some long term anti-arrhythmic benefit.
- Once Atenolol is initiated, anesthetic risk is moderate if needed. **Avoid heart rate stimulating drugs such as atropine or glycopyrrolate unless clinically indicated.** Avoid ketamine and acepromazine due to systemic vascular effects. Pre-oxygenate for 5-10 minutes prior to induction. A reasonable protocol includes opioid/benzodiazepine premedication, propofol or alfaxalone induction, isoflurane gas. Mild IV fluid restriction is advised. Recommend prophylactic antibiotics for any orthopedic or dental procedure in the future given predisposition to endocarditis. Monitor for arrhythmias both intra and post-operatively.
- Monitor for development of labored breathing, exercise intolerance or collapse episodes, as AS patients are more predisposed to development of arrhythmias than to CHF.
- Moderate lifelong exercise restriction is advised.

**PLAN**

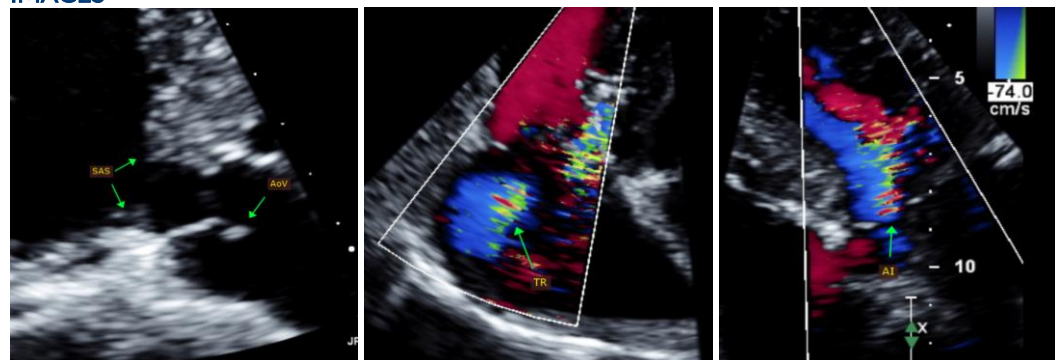
- Recommend conservative monitoring with a recheck echocardiogram in 6-12 months, sooner if any development of clinical signs.

**IMAGING PERFORMED BY**  
Pamela Harrigan,  
RDCS

**HOSPITAL NAME**  
Mass Veterinary Services

**REFERRING VET**  
Dr. Masloski

**IMAGES**

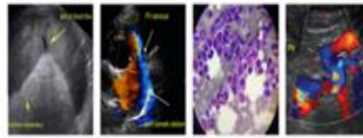


**INVOICE**  
24351

**DATE**  
5/24/22



Mass Veterinary  
Services



**SonoPath**  
Clinical Sonography & Telectology  
EDUCATIONAL TELECONSULTATION SERVICES™  
1-800-838-4268 info@sonopath.com SonoPath.com

**PATIENT**

Lorenzo Wallace

**SPECIES**

Canine

**BREED**

Greyhound

**SEX**

Male Neutered

**AGE**

3 years

**WEIGHT**

77lbs

**INTERPRETED BY**

Maggie Machen  
Lamy, DVM  
DACVIM (Cardiology)

**IMAGING  
PERFORMED BY**

Pamela Harrigan,  
RDCS

**HOSPITAL NAME**

Mass Veterinary  
Services

**REFERRING VET**

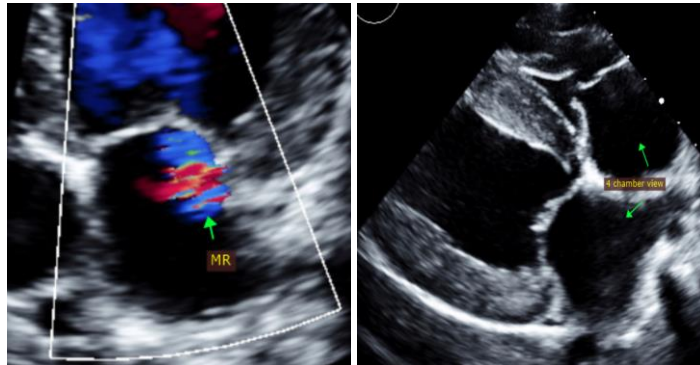
Dr. Masloski

**INVOICE**

24351

**DATE**

5/24/22



The information and recommendations provided are based on the images presented by the referring veterinarian. No evaluation can be communicated regarding pathology that was not visible in the image/video clips provided.

Thank you for this referral. This report was generated using transcription software, and minor dictation errors may be present. If the clinical or image interpretation does not parallel your findings or if I can be of any further assistance, please contact me.

**Maggie Machen Lamy, DVM**  
Diplomate of the American College of Veterinary Internal Medicine (Cardiology)  
info@sonopath.com

**Echocardiogram performed by:** Pamela Harrigan, RDCS  
Pet Animal Ultrasound Service (4paus.com)